



●

Volume 2 / Issue 2 / December 2022

Clinical Report

●

Facial Blanching As An Unusual Complication After The Injection of Local Anesthesia: A Clinical Report

Hilal Erdoğan, DDS, PhD^{1*}

¹*Nevşehir Hacı Bektaş Veli University, Department of Endodontics, Faculty of Dentistry, Nevşehir, Turkey*

**Corresponding author: hilalerdogan@nevsehir.edu.tr*

Erdoğan, Hilal. "Facial Blanching As An Unusual Complication After The Injection of Local Anesthesia: A Clinical Report". *Acta Stomatologica Cappadocia*. 2;2 (December 2022): 64-73.

DOI: <https://doi.org/10.54995/ASC.2.2.5>

Received: 05.12.2022; Accepted: 29.12.2022

This work is licensed under a Creative Commons Attribution-NonCommercial 4.0 International License.



Facial Blanching As An Unusual Complication After The Injection of Local Anesthesia: A Clinical Report

Hilal Erdođan

Abstract

Facial blanching is a complication related to local anesthesia in dentistry. Anatomical variation, intravascular injection, rapid local anesthetic injection, decreased blood flow with the vasopressor effect of epinephrine, ortho-retrograde movement of the solution, incorrect positioning of the needle, and neurological origin may cause this phenomenon, the etiology of which is not fully known. Most of the blanching cases reported in the literature are related to injection of the inferior alveolar nerve block. Also, intra-extraoral clinical photography is limited. Supraperiosteal infiltration anesthesia is a safe and easy technique that is frequently used in daily practice in dental clinics. This unique case report describes partial blanching of the face and gingiva after supraperiosteal infiltration of vasoconstrictor containing local anesthetic into the maxilla. In addition, the clinical-anatomical relationship of facial-mucosal blanching with the injection site, literature information, and clinical management with this complication are explained.

Keywords: Facial Blanching, Ischemia, Skin pallor, Local Anesthetics, Complication, Vasospasm

Introduction

Local anesthetics have an important place in the routine daily practices of dentistry. They provide pain control by reversibly blocking the conduction of sensory nerves.¹ Thus, a comfortable treatment environment for the patient and clinician is provided. In intra-oral local anesthetic injection, considered a safe procedure, the drug is usually administered close to the terminal nerve branch (such as suprapariosteal infiltration, or field block) or nerve trunk (nerve block).² Because the cortical plate of the upper jaw alveolus is thin and porous, infiltration anesthesia is almost always sufficient for maxillary dental procedures.³

Complications caused by the injection of local anesthetics can be local or systemic but are rare.⁴ Anatomical differences or failures in technique can be effective in the development of local complications.⁵ Two common local complications in cases originating from the anatomical region are facial nerve injury and intravascular injections.⁶ Subjective and objective symptoms observed as a result of accidental intravascular local anesthetic injection into the maxillofacial region are palpitation, dizziness, light-headedness, diplopia, vision alternation, burning sensation, and facial blanching.^{3,7-9} These temporary complications resolve completely within 5 to 45 minutes after injection.¹⁰ These complications are more common during inferior alveolar nerve block, but they can also appear with any intra-oral injection where local anesthesia is transmitted into the arterial lumen.^{11,12} In the literature, there are intravascular injection cases related to the posterior superior alveolar artery^{3,13}, superior palatine artery¹², buccal artery¹⁴, facial artery⁴, and mostly inferior alveolar artery.^{9,11,15-17}

Facial blanching has been reported as a complication of local anesthesia in dentistry.^{4,7,11,12} Affecting the terminal branches of the maxillary artery¹⁷, being a reversible end-organ phenomenon¹, explained by the theory of sympathetic vasospasm¹³, and being observed in the distribution of the infraorbital artery¹⁸ are the specific principles of facial blanching.⁷ Neurotoxin injection (botulinum toxin), superpotent corticosteroids, and intravascular administration of cosmetic fillers can be mentioned as other different applications that can cause facial blanching.^{7,19-21}

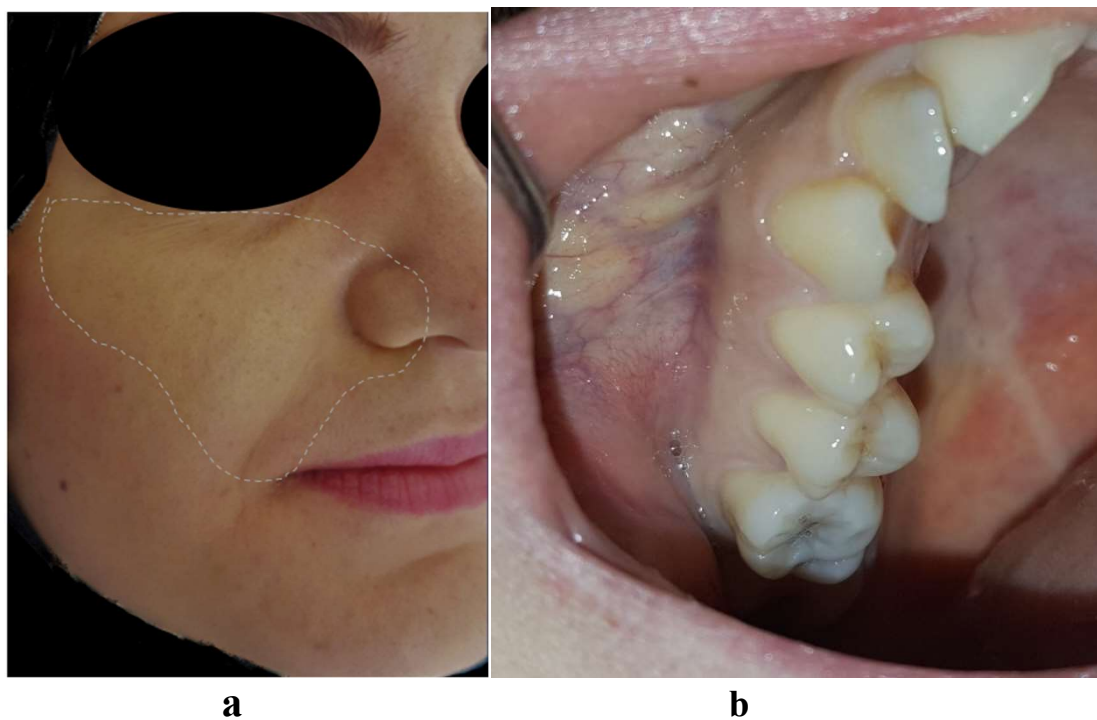
A standard local (suprapariosteal) infiltration anesthesia is an easy technique and is frequently applied in the daily clinic. Within the current knowledge, there is no case in the literature regarding facial blanching after suprapariosteal anesthesia to the maxillary premolar region. This clinical report aims to provide information about the blanching of the face and gingiva after suprapariosteal local anesthesia injection applied to the maxilla and to discuss its effects.

Case

A healthy 23-year-old female was undergoing routine operative dental treatment. Her medical history was non-contributory. A standard local (supraperiosteal) infiltration anesthesia was performed to the upper right first premolar using 1.8 mL of 4% articaine hydrochloride with 1:100,000 epinephrine (Ultracain D-S Forte; Aventis, Istanbul, Turkey) with a 27-gauge needle by the dentist. Negative aspiration was done. Immediately after infiltration, pallor appeared on the same side of the cheek. The patient felt a different sensation in this area and started being anxious. Due to the anxiety of the patient, the opinion of the endodontist was consulted.

Extra-oral examination revealed blanching from under the right eyelid to the infraorbital region, lateral to the nose, above the nasolabial line, and to the corner of the right lip (Fig. 1). In the intra-oral clinical examination, gingival ischemia was observed in the region extending from the maxilla right canine to the first molar. There were no visual or nasal complications in the patient. Subsequently, the patient was notified regarding the complication. It was thought that the cause of the complication might be the rapid administration of the anesthetic, the vasoconstrictive effect of the epinephrine in the anesthetic solution, or anatomical variations.

Figure 1. Skin ischemia after a supraperiosteal infiltration a) Facial blanching in the anatomic circulation of the infraorbital artery. b) Intra-oral view of gingival ischemia



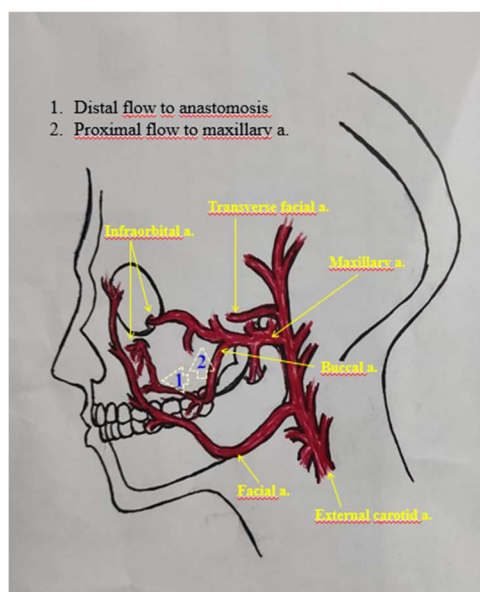
Within 15 minutes, the areas had returned to normal with no persisting symptoms. A standard restorative dental treatment was successfully applied to the maxillary right first premolar.

Discussion

Local anesthetics are widely used in dentistry and can be applied with different techniques, but the literature on its complications is limited. Facial blanching as a result of intravascular injection of local anesthetics is most commonly associated with an inferior alveolar nerve block.^{7,11,12}

Anatomy in the facial area may differ from person to person. The facial blanching occurred in the present case may be relevant to the branches of the infraorbital artery, which is the terminal part of the maxillary artery. The infraorbital artery, one of the distal branches of the maxillary artery, enters the face via the infraorbital foramen and supplies lower eyelid, lateral nose, and the cheek.²² It is stated that the infraorbital, buccal, and facial arteries can anastomose.²³⁻²⁵ Cheek pallor has been reported after injecting epinephrine into the buccal (buccinator) artery, a branch of the middle third of the maxillary artery.¹⁴ The hypothesis of the probable cause is that the anesthetic solution goes forward distally (orthograde) along the anastomosis to reach the infraorbital artery originating from the foramen, or proximal (retrograde) direction to the maxillary artery and from the infraorbital canal to the infraorbital artery region (Fig. 2).¹⁴ While both pathways affect the facial skin, the second pathway can also affect the ocular adnexa.¹⁴

Figure 2. Maxillary artery anastomoses and local anesthetic distribution direction hypothesis to distal (orthograde)/proximal (retrograde).¹⁴



There are differences in anesthetic preference in different countries, lidocaine and articaine are widely used.²⁶ The vasoconstrictor components in the local anesthetic solution may also cause blanching of the face in case of intravascular injection.¹⁴ Epinephrine is present in combination with local anesthetics, promoting vasoconstriction through agonistic activity on α 1-adrenergic receptors, slowing systemic drug uptake, and prolonging anesthesia time.^{4,16,26} Epinephrine in the anesthetic generates vasoconstriction throughout the branches of the vessels near the injection area or intravenous injection carries the anesthetic solution to the periphery.²⁷ It is stated that injections administered quickly and with pressure may cause some anesthetic solution to be carried in a retrograde direction.²⁸ In the present case, rapid administration of the injection may have caused the reverse flow of the solution²², so that the anesthetic solution could induce reflective vasospasm of infraorbital artery³. Vasoconstrictive activity is mediated by the sympathetic adrenoceptor response in the arteriole wall and smooth muscle contraction.¹⁴

The vasoconstriction induced in peripheral blood vessels by epinephrine, a vasopressor agent, reduces blood flow.⁹ In the present case, an arterial spasm spreading through the vascular connections described above may be another cause of facial and gingival blanching. Also, the abundance of terminal branches of the infraorbital artery and the presence of angular-transverse anastomosis with the facial artery are determinants of the size of the facial blanching zone.^{7,29,30} However, it was also stated that there is no need for vasoconstrictors in the formation of facial blanching.⁷

Facial blanching may also occur in cases where there is no positive aspiration during the injection. Aspiration is advised before local anesthetic injection to avoid accidental intravascular administration and potential unwanted local and/or systemic complications.¹ However, aspiration may not always be valid or correct in cases where syringes with unsharpened harpoons do not grip the plunger effectively or in false-negative aspiration.^{3,4,17} Sudden pain, heart palpitations, skin pallor/ischemia, or inadequate anesthesia may occur in cases where local anesthetics containing vasoconstrictors are accidentally injected intravenously.^{3,11,13,17} Local anesthesia has been observed to be successful in current and similar cases, which can be explained by the theory that needle contact with the perivascular sympathetic plexus or the passing of the needle near the artery is sufficient to trigger facial blanching.⁷

The majority of reported cases of local anesthesia and blanching, including the present case, are young individuals. In a case where the patient's age was over the third decade, it was

stated that the age-related deterioration of the sympathetic regulation of the peripheral cutaneous vascular system was associated with this condition.^{7,31}

This complication can be seen after intra-oral as well as extra-oral injections of local anesthesia. Therefore, in cases where cutaneous surgery will be performed, the patient and operator should know about this local anesthesia complication. The temporary nature of this phenomenon observed after local anesthetic injection is different from skin pallor after administration of cosmetic fillers. In the latter condition, immediate treatment with hyaluronidase, topical nitro pastes, and warm compresses should be applied.³²

The probability of this phenomenon can be decreased by preferring areas with relatively low vascular density for the application of local anesthesia techniques. Aspiration is significant to avert this complication. If complications are observed, the patient should be promptly informed and guided to remain calm. The best clinical management of this complication is to stop the injection immediately, notify the patient formally, and reassure the patient of the temporary and reversible nature of the anesthetic and/or vasoconstrictive effects.^{4,14} There was no ocular complication in this case. A formal ophthalmic assessment, including eye movements, visual acuity, and corneal sensation, should be performed for all ocular problems, and the lids should be closed prophylactically as needed.¹⁴

Conclusion

The well-known characteristic of this phenomenon, seen after the injection of a local anesthetic, is skin ischemia. After supraperiosteal infiltration, a simple technique, there may be facial blanching in the circulation region of the infraorbital artery, as in the inferior alveolar nerve block. Having sufficient information about this self-limiting temporary complication can ensure that the dentist and the patient remain composed, so unnecessary treatments can be prevented.

References

1. Blanton PL, Jeske AH. ADA Council on Scientific Affairs, ADA Division of Science. Avoiding complications in local anesthesia induction: anatomical considerations. *J Am Dent Assoc* 2003;134:888-93.
2. Garcia-Blanco M, Gualtieri AF, Puia SA. A randomized controlled trial comparing nerve block and mandibular infiltration techniques in posterior mandible implant surgeries. *J Clin Exp Dent* 2018;10:e1003-e10.
3. Scarano A, Sinjari B, Lorusso F, Mortellaro C, et al. Intense, Instantaneous, and Shooting Pain During Local Anesthesia for Implant Surgery. *J Craniofac Surg* 2018;29:2287-90.
4. Garcia-Blanco M, Scanlan S. Accidental Intravascular Local Anesthetic Injection of the Facial Artery. *Anesth Prog* 2021;68:29-32.
5. Khoury J, Mihailidis S, Ghabriel M, Townsend G. Anatomical relationships within the human pterygomandibular space: Relevance to local anesthesia. *Clin Anat* 2010;23:936-44.
6. Holliday R, Jackson I. Superior position of the mandibular foramen and the necessary alterations in the local anaesthetic technique: a case report. *Br Dent J* 2011;210:207-11.
7. Rahpeyma A, Khajehahmadi S. Facial Blanching after Local Anesthesia Injection: Clinico-anatomical Correlation-Review of Literature. *J Cutan Aesthet Surg* 2020;13:1-4.
8. Meyer FU. Complications of local dental anesthesia and anatomical causes. *Ann Anat* 1999;181:105-6.
9. Webber B, Orlansky H, Lipton C, Stevens M. Complications of an intra-arterial injection from an inferior alveolar nerve block. *J Am Dent Assoc* 2001;132:1702-4.
10. Uckan S, Cilasun U, Erkman O. Rare ocular and cutaneous complication of inferior alveolar nerve block. *J Oral Maxillofac Surg* 2006;64:719-21.
11. Kang SH, Won YJ. Facial blanching after inferior alveolar nerve block anesthesia: an unusual complication. *J Dent Anesth Pain Med* 2017;17:317-21.
12. McCormick RS, Adams JR. Blanching of facial skin after infiltration of local anaesthetic: an unusual complication of inadvertent intra-arterial injection. *Br J Oral Maxillofac Surg* 2016;54:1051-2.
13. Kronman JH, Giunta JL. Reflex vasoconstriction following dental injections. *Oral Surg Oral Med Oral Pathol* 1987;63:542-4.
14. Herd MK, Smith RJ, Brennan PA. Long buccal nerve block: a previously unreported complication. *Oral Surg Oral Med Oral Pathol Oral Radiol Endod* 2011;112:e1-3.

15. Aravena PC, Valeria C, Nunez N, Perez-Rojas F, et al. Skin and mucosal ischemia as a complication after inferior alveolar nerve block. *Dent Res J (Isfahan)* 2016;13:560-3.
16. Ezirganli S, Kazancioglu HO. An unforeseen complication arising from inferior alveolar nerve block: is anemia possible? *J Craniofac Surg* 2013;24:2178-9.
17. Paul R, Anand R, Wray P, D'sa S, et al. An unusual complication of an inferior dental nerve block: a case report. *Br Dent J* 2009;206:9-10.
18. Kim HS, Lee KL, Gil YC, Hu KS, et al. Topographic Anatomy of the Infraorbital Artery and Its Clinical Implications for Nasolabial Fold Augmentation. *Plast Reconstr Surg* 2018;142:273e-80e.
19. Hessel A, Zyniewicz K. Facial blanching caused by superpotent corticosteroids. *Cutis* 1991;48:395.
20. DeLorenzi C. Complications of injectable fillers, part 2: vascular complications. *Aesthet Surg J* 2014;34:584-600.
21. Khan TT, Herne K, Dayan SH, Woodward JA. Facial blanching due to neurotoxins: proposed mechanisms. *Dermatol Surg* 2013;39:24-9.
22. Ulutürk H, Eberlikose G, Özcan G, Yilmaz D. Rare Cutaneous Ischemia and Pain during Infiltrative Anaesthesia for Dental Surgery: Case Reports and Literature Review. *J Clin Diagn Res* 2020;14:1-4.
23. Standring S. *Gray's anatomy e-book: the anatomical basis of clinical practice*. 42th ed. Philadelphia: Elsevier Health Sciences; 2021.
24. Romanes GJ. *Cunningham's manual of practical anatomy*. 15th ed. Oxford: Oxford University Press 1986.
25. Constanza AK, Marta AM, Ignacio NC. Facial artery, an essential anatomy in different specialties: a review. *J Otolaryngol ENT Res* 2022;14:14-20.
26. Boonsiriseth K, Chaimanakarn S, Chewpreecha P, Nonpassopon N, et al. 4% lidocaine versus 4% articaine for inferior alveolar nerve block in impacted lower third molar surgery. *J Dent Anesth Pain Med* 2017;17:29-35.
27. Lustig JP, Zusman SP. Immediate complications of local anesthetic administered to 1,007 consecutive patients. *J Am Dent Assoc* 1999;130:496-9.
28. Freuen ND, Feil BA, Norton NS. The clinical anatomy of complications observed in a posterior superior alveolar nerve block. *FASEB J* 2007;21:A967.

29. Hufschmidt K, Camuzard O, Balaguer T, Baque P, et al. The infraorbital artery: From descriptive anatomy to mucosal perforator flap design. *Head Neck* 2019;41:2065-73.
30. Pinar YA, Bilge O, Govsa F. Anatomic study of the blood supply of perioral region. *Clin Anat* 2005;18:330-9.
31. Greaney JL, Alexander LM, Kenney WL. Sympathetic control of reflex cutaneous vasoconstriction in human aging. *J Appl Physiol* (1985) 2015;119:771-82.
32. Lin B, Eisen DB. Facial blanching after cutaneous injections: cannulation of branches of the ophthalmic artery. Case series and review of the literature. *Dermatol Surg* 2011;37:530-5.